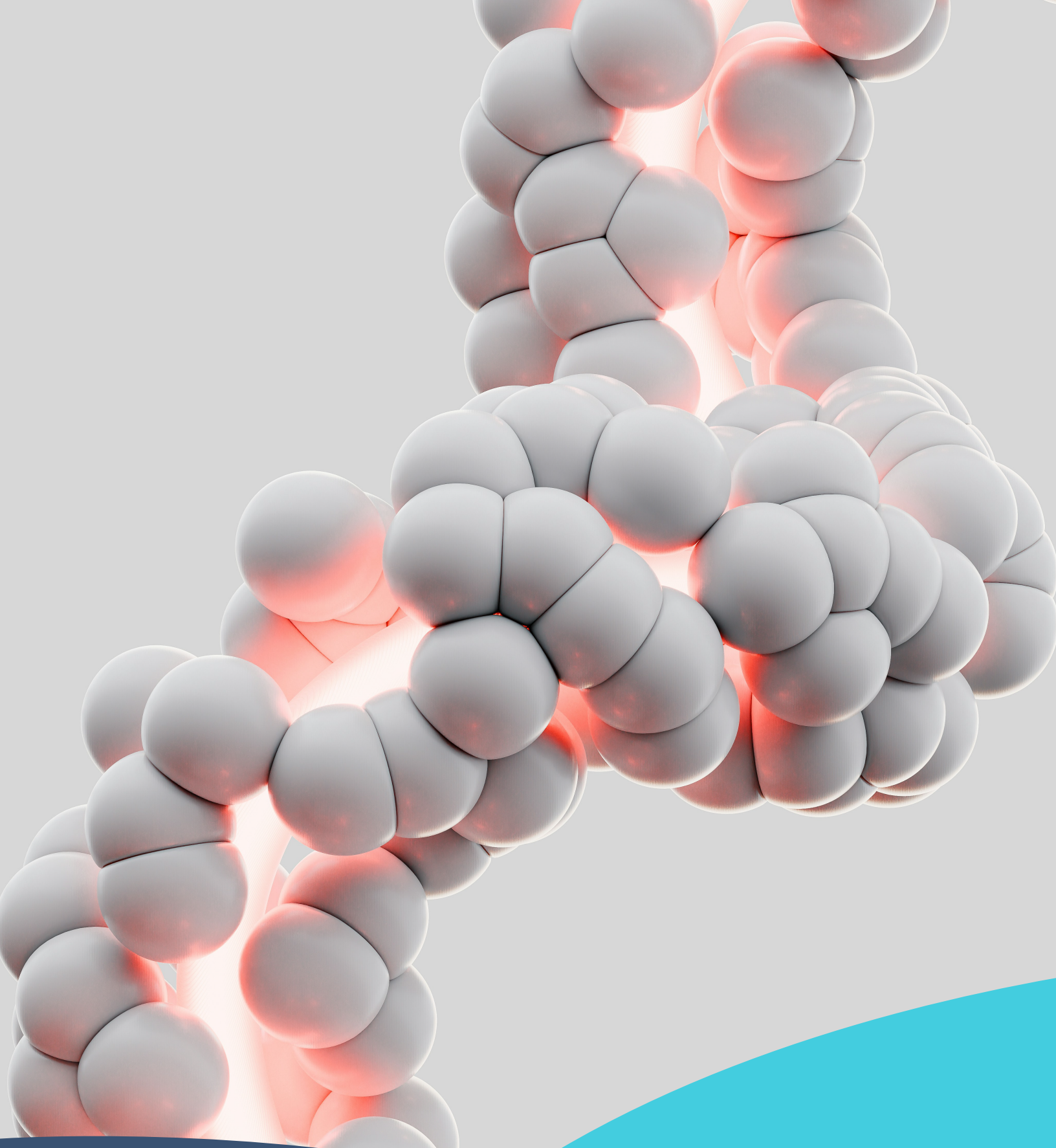

NeuroVision Associates
CHARLES SHIDLOFSKY, O.D., FOVDR, FNAP

When Blood Sugar Inflames the Brain, Vision Feels It First

NOVEMBER 2026 | EDITION 3

When Blood Sugar Inflames the Brain, Vision Feels It First

Part 2 of a Series on Neuro-Inflammation and the Visual System: Metabolic Inflammation

"No Diabetic Retinopathy." So Why Doesn't My Vision Feel Right?

Your vision is blurry in the afternoon and clear again by morning. Your reading glasses work fine one week and not the next. Screens wear you out faster than they used to. Driving at night feels harder, even though your prescription hasn't changed much.

You've had your dilated diabetic eye exam, and the news was good: no bleeding, no leaky blood vessels, no diabetic retinopathy. Maybe your doctor has told you your A1c is "a little high" or that you're "prediabetic." Maybe nobody has checked it at all.

In Part 1 we covered inflammation set off by an injury or by the immune system. This installment is about a quieter cause that's far more common in North Texas: **metabolic inflammation**, the slow, low-grade inflammation that comes with high blood sugar, insulin resistance, and excess body fat.

Retinopathy Is Not the First Thing To Go Wrong

For decades, diabetic eye disease has been defined by what we can see at the back of the eye: tiny hemorrhages, leaking vessels, swelling. It's been treated as a blood vessel disease, and the standard diabetic eye exam is built to find those vessel changes.

The nerve tissue, though, appears to be affected first. A four-year study of people with diabetes and little or no retinopathy found steady, progressive thinning of the retina's nerve fiber and ganglion cell layers, the wiring that carries the visual signal to the brain. Donor eyes from people with diabetes had much thinner nerve fiber layers than non-diabetic eyes, even though the density of their small blood vessels was no different. The authors' conclusion was that nerve damage may come before the vascular changes the standard exam looks for. **[1]**

It also starts before the diagnosis. Among more than 41,000 UK Biobank participants, people with undiagnosed diabetes already had thinner retinal layers. Even people whose A1c was in the upper part of the normal range had slightly but measurably thinner photo receptor layers. **[2]**

Read that again: the changes can be measured before anyone has made the diagnosis.

> The **nerve tissue** appears to be affected first. People with undiagnosed diabetes already had **thinner retinal layers.**

What "Metabolic Inflammation" Actually Means

Part 1 introduced microglia, the brain's resident immune cells, which switch into defense mode when the brain is under threat. An injury is one kind of threat. A chronically unbalanced metabolism is another.

When blood sugar stays high, it creates oxidative stress and advanced glycation end products (AGEs), proteins damaged by sugar that the immune system recognizes as a danger signal. A systematic review of 267 studies concluded that diabetes and its main features push microglia in both the brain and the retina into an activated, pro-inflammatory state. The microglia change shape, release inflammatory cytokines, and increase oxidative stress. **[3]**

Diet can start this process remarkably fast. In rats and mice, a high-fat diet set off inflammatory signaling in the hypothalamus within one to three days, before any meaningful weight gain. As the diet continued, the inflammation became permanent. The same research group found MRI evidence of similar changes in the hypothalamus of people with obesity. **[4]**

With trauma, there's a single moment of injury. Metabolic inflammation is a slow burn that keeps going every day the metabolic picture stays out of balance. That's why it' easy to miss, and also why it responds to change.



Metabolic inflammation is a slow burn that keeps going.

How It Shows up in the Visual System

In Part 1 we described three features that make the visual system especially vulnerable: long, myelinated wiring; high energy demand; and the need for precise timing. Metabolic inflammation affects all three.

- The signal slows down. Pattern VEP testing in people with diabetes but no retinopathy and no peripheral neuropathy found a delayed P100 response and a smaller amplitude compared with healthy controls. The longer someone had had diabetes, the greater the delay. **[5]** The visual pathway was slowing before either the eye exam or the foot exam showed anything

.

- Ganglion cells struggle before they show damage. Combined pattern ERG and pattern VEP testing has detected reduced ganglion cell function, along with a thinner ganglion cell layer, in diabetic eyes that had no visible retinopathy. **[6]**

- Function predicts structure. In patients with diabetes and no retinopathy, delays in the multifocal ERG predicted where in the retina retinopathy would appear a year later, with about 80% sensitivity. **[7]**

- Focus fluctuates. Blood sugar changes the optics inside the eye. When severe high blood sugar was brought under control, every patient in one study developed a temporary farsighted shift, as large as 3.75 diopters, that took two to twelve weeks to resolve. The faster glucose came down, the bigger the shift. **[8]**

What patients actually feel is rarely "I can't see the chart." It's blur that comes and goes over the day, focusing fatigue at near, poor contrast in dim light and at night, eye strain on screens, and a foggy, effortful quality to visual work that often tracks with how stable their blood sugar has been. As with trauma, these are mostly timing, endurance, and stability problems, not sharpness problems, and that's exactly what a 20/20 chart doesn't measure.

Important: sudden double vision, a drooping eyelid, or new eye pain in someone with diabetes or prediabetes needs prompt medical evaluation. Diabetes can affect the nerves that control eye movement, and those symptoms can also signal other conditions that need urgent care.

Where We Can See It

As in Part 1, objective testing turns "something feels off" into a measurable finding. **The Visual Evoked Potential (VEP)** shows how long the visual signal takes to reach the visual cortex and how strong it is when it arrives. As the research above shows, that timing can be delayed in people with diabetes well before retinopathy appears.

Paired with **EEG/ERP testing**, which shows how efficiently the brain processes information, these results give us a functional baseline. Because metabolic inflammation can improve, retesting matters: it lets us, and the patient, see whether the visual system is responding as their metabolic health changes.

The Good News: This One Can Change

Some causes of neuro-inflammation are hard to influence. Metabolic inflammation is different. It's driven largely by things that change from day to day: what we eat, how we sleep, how much we move, and how well blood sugar is controlled.

Managing blood sugar itself belongs with your primary care physician or endocrinologist, and we coordinate with them. Our role is the functional side:

- **Measure what the visual system is doing, s**o improvement (or the lack of it) is documented objectively, not guessed at.
- **Prescribe wisely during transitions.** If your glucose control is changing quickly, your prescription may shift temporarily. Sometimes the right call is to wait a few weeks before ordering new glasses.
- **Reduce the load and rebuild the skills.** Therapeutic lenses and prism can ease the strain on an overloaded system, and vision therapy can retrain focusing, eye teaming, and visual endurance.
- **Address the inflammation itself.** We talk with patients about anti-inflammatory eating patterns, such as a Mediterranean-style diet that's lower in refined carbohydrates and sugar, as part of the overall plan, alongside their medical team.

What This Means for You

"No diabetic retinopathy" is good news, and you should keep getting your annual dilated eye exam. But it means your retinal blood vessels look healthy. It doesn't mean your visual system is working at full speed, full endurance, or full stability.

If you have diabetes or prediabetes, or have been told your blood sugar is "borderline" and your vision doesn't feel the way it should, that's worth a closer look. In this case the earlier we look, the more there is to gain.

Coming in this series:

- **Part 1 (published)**: Trauma and immune-driven inflammation, covering concussion, brain injury, MS, and autoimmune conditions.
- **Part 3**: The neurodegenerative conditions, where visual changes in dementia and Parkinson's often show up years before the diagnosis.
- **Part 4**: Lyme disease, chronic infection, and dysautonomia/POTS. These patients are the most often dismissed, and often the ones with the most to gain.

Living With Diabetes or Prediabetes and Vision That Doesn't Feel Right?

A neuro-optometric evaluation at NVANT looks at the parts of your visual system a routine exam doesn't test: focusing stability, eye teaming, tracking, visual endurance, and, where indicated, objective VEP and EEG/ERP electrophysiology. If what you've read here sounds familiar, we'd welcome the chance to take a closer look.

REFERENCES

[1] Sohn EH, et al. Retinal neurodegeneration may precede microvascular changes characteristic of diabetic retinopathy in diabetes mellitus. Proc Natl Acad Sci U S A. 2016. doi:10.1073/pnas.1522014113 (human and animal)

[2] Chua SYL, et al. Associations between HbA1c across the normal range, diagnosed, and undiagnosed diabetes and retinal layer thickness in UK Biobank cohort. Transl Vis Sci Technol. 2023. doi:10.1167/tvst.12.2.25

[3] Vargas-Soria M, et al. Effects of diabetes on microglial physiology: a systematic review of in vitro, preclinical and clinical studies. J Neuroinflammation. 2023. doi:10.1186/s12974-023-02740-x

[4] Thaler JP, et al. Obesity is associated with hypothalamic injury in rodents and humans. J Clin Invest. 2012. doi:10.1172/JCI59660 (animal and human)

[5] Ashok K, et al. Utility of visual evoked potentials in the evaluation of visual pathway dysfunction in diabetics without retinopathy. Rom J Ophthalmol. 2024. doi:10.22336/rjo.2024.22

[6] Nehme J, et al. Pattern ERG, pattern VEP, and GCL thickness in diabetic patients with no diabetic retinopathy. J Fr Ophtalmol. 2025. doi:10.1016/j.jfo.2025.104513 (pilot study)

[7] Harrison WW, et al. Multifocal electroretinograms predict onset of diabetic retinopathy in adult patients with diabetes. Invest Ophthalmol Vis Sci. 2011. doi:10.1167/iovs.10-5931

[8] Okamoto F, et al. Refractive changes in diabetic patients during intensive glycaemic control. Br J Ophthalmol. 2000. doi:10.1136/bjo.84.10.1097

This document does not contain medical advice.

Have A Question? Let Us Know!

frontdesk@dr-s.net